

# Pregnancy with frozen–thawed and fresh testicular biopsy after motile and immotile sperm microinjection, using the mechanical touch technique to assess viability

Neuda Marques de Oliveira<sup>1</sup>, Rebeca Vaca Sánchez, Sonsoles Rodriguez Fiesta, Tomas Lopez Salgado, Rubi Rodríguez, Jose C.Alberto Bethencourt and Raquel Blanes Zamora

Hospital Universitario de Canarias (HUC), Servicio de Ginecología y Obstetricia, Unidad de Reproducción Humana, Carretera General, Ofra S/N La Cuesta, 38320 La Laguna, Santa Cruz de Tenerife, Spain

<sup>1</sup>To whom correspondence should be addressed. E-mail: neudam@hotmail.com

**BACKGROUND:** There are few reports of pregnancy using immotile sperm, and none using a purely mechanical assessment of viability. **METHODS:** In this pilot study, we retrospectively analysed 66 cycles in 61 patients with determinant male factor, recording rates of fertilization, implantation, normal pregnancy and take-home babies achieved with ICSI. Sperm selection was based on morphologically normal appearance under the inverted microscope. Viability of immotile spermatozoa was assessed by the mechanical touch technique to observe tail flexibility and tail shape recovery. **RESULTS:** Of 17 ICSI cycles using frozen–thawed testicular sperm, six microinjected with immotile and 11 with motile sperm, we achieved fertilization rates of 65.7 and 74.3%, respectively, and five pregnancies (two and three, respectively). Of 49 ICSI cycles using fresh testicular sperm, 10 microinjected with immotile and 39 with motile sperm, we achieved fertilization rates of 73.4 and 64.4%, respectively, and 12 pregnancies (three and nine, respectively). **CONCLUSIONS:** Immotile (fresh and frozen–thawed) testicular sperm of normal morphological appearance can be used to achieve clinical pregnancy with ICSI. Our results strongly suggest that immotile sperm viability can be assessed by the mechanical touch technique.

*Key words:* ICSI/immotility/pregnancy/sperm viability

## Introduction

The treatment of male determinant factor has been revolutionized by ICSI (Palermo *et al.*, 1992). Patients with azoospermia were previously considered untreatable.

Schoysman *et al.* (1993a,b) were the first to report fertilization and pregnancy after ICSI with sperm obtained by testicular sperm extraction (TESE). Even in cases of testicular failure, TESE can be used successfully (Devroey *et al.*, 1996).

Case reports of successful ICSI with frozen–thawed testicular motile sperm have been published (Fisher *et al.*, 1996; Hovatta *et al.*, 1996; Podsiadly *et al.*, 1996; Khalifeh *et al.*, 1997), but there are few reports of success with immotile sperm (Shulman *et al.*, 1999). Nagy *et al.* (1995) stressed the role of sperm motility for successful outcome of ICSI, and in 1998 reported lower rates of fertilization associated with non-motile testicular sperm. However, the criteria for selection of viable immotile sperm were not reported.

In many studies, the hypo-osmotic swelling test (HOS) (Casper *et al.*, 1996; Liu *et al.*, 1997) was used to determine the viability of immotile sperm. Some controversy surrounds this test or variants thereof owing to the deleterious effect it may have on sperm vitality. To our knowledge, this is the first study to report normal pregnancy after ICSI using immotile sperm

where viability was assessed using the mechanical touch technique, which seems not to harm the sperm in any way. This is of considerable importance since, without such assessment, the transfer of non-viable sperm is possible, which might explain the poorer outcome.

We retrospectively studied fertilization, cleavage, implantation, pregnancy and take-home baby rates achieved using four combinations of fresh and frozen–thawed motile and immotile testicular sperm judged to be of normal morphological appearance under the inverted microscope.

## Materials and methods

### Patients

We treated 61 Caucasian couples (female age range 23–39 years; male age range 30–45 years) diagnosed with male determinant factor. Between July 2001 and May 2002, 66 TESE-ICSI cycles were carried out, 49 with fresh and 17 with frozen–thawed testicular sperm. Diagnosis in all cases was obstructive azoospermia. Chromosomal analysis revealed a normal karyotype in all patients.

### Ovarian stimulation

Pituitary suppression was achieved by using a long GnRH analogue (Decapeptyl; Ipsen, Barcelona, Spain) protocol, followed by ovarian

**Table I.** Comparison between frozen–thawed TESE with immotile (group I) and motile (group II) sperm and fresh TESE with immotile (group III) and motile sperm (group IV)

	Group I	Group II	Group III	Group IV	<i>P</i> (Mann–Whitney <i>U</i> -test)
No. of patients	6	11	10	34	
No. of cycles	6	11	10	39	
Mean female age (range)	32.7 (25–38)	33.9 (24–39)	31.2 (23–37)	32.0 (23–39)	NS
Mean male age (range)	37.2 (30–45)	35.8 (30–43)	37.1 (30–45)	37.5 (30–45)	NS
Fertilization (%)	65.7	74.3	73.4	64.4	NS
Mean MII oocytes ( $\pm$ SD)	10.0 $\pm$ 1.2	10.6 $\pm$ 1.1	8.9 $\pm$ 2.1	8.6 $\pm$ 2.4	NS
% Embryo cleavage	95.4	86.5	97.5	88.0	NS
No. of embryos transferred	18	29	24	94	
Mean no. of embryos transferred ( $\pm$ SD)	3.0 $\pm$ 0.2	3.0 $\pm$ 0.2	2.4 $\pm$ 1.3	2.5 $\pm$ 1.2	NS
Implanted	2	4	3	10	
No. of pregnancies	2	3 <sup>a</sup>	3	9 <sup>b</sup>	
Pregnancies/embryo transferred (%)	11.1	10.3	12.5	9.6	NS
Pregnancies/patient (%)	33.3	27.3	30	26.5	NS
Implanted (%)	11.1	13.8	12.5	10.6	NS
Pregnancies/cycle (%)	33.3	27.3	30.0	23.1	NS
Miscarriage (%)	0	1 (33.3)	0	1 (11.1)	NS
Take home baby (%)	2 (100)	3 (75)	3 (100)	9 (90)	NS

<sup>a</sup>Two single and one twin pregnancy.

<sup>b</sup>Eight single and one twin pregnancy.

stimulation with recombinant FSH (Gonal; Serono Laboratories, Madrid, Spain). Transvaginal ultrasound-guided follicle puncture took place 36–38 h after HCG injection. The cumulus–corona cells were initially removed by exposure to a flushing medium (Medicult; Copenhagen, Denmark) and 80 IU/ml of hyaluronidase (Hyaluronidase type IV-S, St Louis, MO) for 1 min. After removing the corona cells, only metaphase II oocytes were injected.

For the 61 couples treated, a testicular diagnostic biopsy was performed prior to treatment, providing samples for cryopreservation. Production of a fresh semen sample was also tried in each case during the stimulation cycle. In order to avoid a further testicular biopsy in certain cases, frozen–thawed samples of normal morphological appearance were used. We divided the 66 cycles into four groups, as follows: group I, frozen–thawed TESE with immotile sperm (six patients, six cycles); group II, frozen–thawed TESE with motile sperm (11 patients, 11 cycles); group III, fresh TESE with immotile sperm (10 patients, 10 cycles); and group IV, fresh TESE with motile sperm (34 patients, 39 cycles).

#### Retrieval of sperm from testicular tissue

Testicular sperm were obtained by open diagnostic testicular biopsy under local anaesthetic. A small incision was made in the scrotal skin and carried through the peritoneal tunica vaginalis. One or more incisions were made in the tunica albuginea, and a piece of the extruding testicular tissue was excised and placed in flushing medium (Medicult, Denmark). This tissue was dissected with the aid of two sterile scalpels. The fluid content of the dish was aspirated using an automatic pipette and then incubated at 37°C and 5% CO<sub>2</sub>. Just before the microinjection procedure, the fluid content was centrifuged at 600 g for 5 min.

#### Cryopreservation and thawing of testicular sperm

Before freezing, 1 ml of test yolk buffer cryopreservation medium containing glycerol (Irvine Scientific, Santa Ana, CA) was added to 2 ml of sperm suspension at room temperature. The mixture was homogenized and placed in a 4°C bath for 45 min. Thereafter, the mixture was again homogenized and dispensed with the aid of an automatic pipette in 100  $\mu$ l droplets on a dry ice surface (Nagase, 1964). Freezing of droplets occurred as soon as ~1 min. Frozen

droplets (pills) were plunged into liquid nitrogen (–196°C) and stored in 1 or 2 ml cryotube vials (Lab-Tek, Nalge Nunc International).

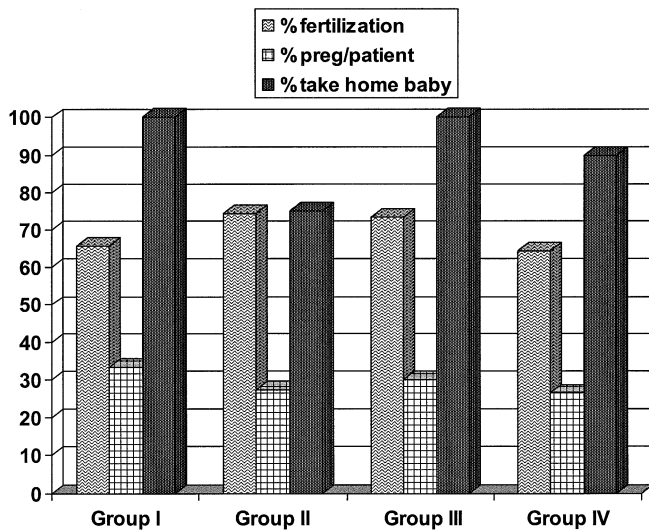
For thawing, the pills were removed from the liquid nitrogen and placed in a 5 ml Falcon tube (Beckton and Dickinson, Lincoln Park, NJ) for 5 min at room temperature. The tube with the pills was then placed at 37°C in a 5% CO<sub>2</sub> chamber for 15 min. To remove the cryopreservation medium, the specimens were washed by centrifugation with 2 ml of IVF medium (Medicult, Copenhagen, Denmark) at 600 g for 5 min. Once the supernatant was eliminated, the pellet was re-suspended in 100  $\mu$ l of IVF medium. This final suspension was incubated at 37°C and 5% CO<sub>2</sub> for 1 h. Thereafter, the presence of morphologically normal sperm for ICSI was checked under an inverted microscope at 100 $\times$  magnification (Diaphot; Nikon Corporation, Tokyo, Japan). In some cases, we found only immotile morphologically normal sperm.

Strict normal morphology can only be judged after staining and observation at 1000 $\times$  magnification, but the procedure renders the sperm non-viable. Our approach is to avoid using morphologically abnormal sperm, rather than try for perfectly formed samples. This is possible at 100 $\times$  magnification, despite the limitation of magnification and optics of the inverted microscope.

#### Mechanical assessment of sperm viability

In our centre, sperm viability is assessed mechanically for a number of reasons. First, some controversy surrounds the use of the HOS test (Barros *et al.*, 1997), with associated low fertilization rates (Casper *et al.*, 1996), and non-viability of sperm after 30 min of incubation in hypo-osmotic solution (Tsai *et al.*, 1997). Secondly, in daily practice, our biologists have to work with extremely limited quantities of testicular sperm in many cases, and the HOS test involves dilution of the sample. Finally, our results have consistently suggested the reliability of mechanical testing.

The mechanical touch technique used in our centre involves laterally pressing against the upper third of the immotile spermatozoon tail and the ICSI dish with the ICSI micropipette (Humagen), much as is routinely done to immobilize motile sperm, thus forcing the tail to one side: The micropipette is raised, and the response is observed. If the tail is flexible and recovers its original position, it is considered viable. Sperm rigidity and incapacity to recover the initial



**Figure 1.** Fertilization, pregnancy per patient and take-home baby rates per group.

tail position is considered a sign of non-viability. The success and reliability of this technique depend largely on the expertise of the biologist performing the assessment.

#### Statistical analysis

Results for categorical variables are expressed as percentages, and continuous variables as means and range. Fertilization, cleavage, pregnancy, implantation and normal birth frequencies were compared using the  $\chi^2$  test. Mean patient age, number of metaphase II (MII) oocytes and embryos were compared using the Mann–Whitney *U*-test. All reported *P*-values are two-sided; a *P*-value of  $<0.05$  was considered statistically significant. We used Horus-Sigma statistics software for statistical analysis.

#### Results

Seventeen take-home babies were born at the close of this study; five of these were achieved using immotile sperm. A single gestational sac was seen in 15 cases, while twin pregnancies occurred in two cases. Amniocentesis was normal in all pregnancies. Subsequently, two pregnancies (with normal chromosomal analyses) were lost at weeks 8 and 12 due to obstetric factors.

No significant differences were found between the groups with regard to the parameters studied (Table I; Figure 1). Male and female patient age, and number of cycles per patient in each group were similar. Interestingly, fertilization rates of 65.7 and 73.4% achieved in groups I and III with immotile sperm (frozen–thawed and fresh, respectively) were similar to those of 74.3 and 64.4% achieved using motile sperm (frozen–thawed and fresh, respectively). Embryo cleavage rates were slightly higher in groups I (95.4%) and III (97.5%) where immotile sperm was used, as compared with groups II (86.5%) and IV (88.0%). The average number of embryos transferred was not statistically different between groups.

With regard to the number of normal pregnancies, the following results were found: of six patients in group I, there were two pregnancies, both singletons (33.3% per cycle). Of 11

patients in group II, there were three pregnancies, two singletons and one twin (27.3% per cycle). Of 10 patients in group III, there were three singleton pregnancies (30.0% per cycle). Finally, of 34 patients in group IV, there were nine pregnancies, all singletons except for one twin (25.1% per cycle).

Immotile sperm was used in 16 patients (26.4% of the study population) and yielded five successful pregnancies (32%) with no miscarriages. Motile sperm was used in 45 patients (73.6% of the study population), yielding 12 successful pregnancies (20.6%), and we recorded two miscarriages.

After immotile sperm injection, a total of 42 embryos (18 from group I and 24 from group III) were transferred, of which five (two and three, respectively) implanted (12%). Using motile sperm, a total of 123 embryos (29 from group II and 94 from group IV) were transferred, of which 14 (four and 10, respectively) implanted (11.4%).

In summary, it is notable that no significant differences were found on comparing fertilization, pregnancy per patient and take-home baby percentages achieved using immotile (fresh and frozen–thawed) sperm versus motile (fresh and frozen–thawed). This finding indirectly suggests the reliability of the mechanical touch technique.

#### Discussion

Classically, sperm morphology and motility were considered to play an important role in fertilization and pregnancy rates in ICSI. Sperm motility is clearly an indicator of viability, but the reverse is not necessarily true. Immotility itself does not preclude viability.

Currently, viability is the fundamental criterion for selecting sperm in assisted human reproduction techniques. Thus, the technique chosen to evaluate viability is of great importance. The traditional HOS test was declared unsuitable for ICSI by the World Health Organization (1992) because many live spermatozoa became non-viable after 30 min of incubation in the hypo-osmotic solution used at that time. Later researchers introduced modified HOS tests (Casper *et al.*, 1996; Liu *et al.*, 1997), with relatively low rates of fertilization and pregnancy. In our centre, the technique used to assess viability of immotile sperm avoids chemical solutions that may prejudice outcome. Our relatively high rates of fertilization and pregnancy strongly suggest that the mechanical assessment of viability is reliable.

In our study, no significant differences were found in fertilization rate when fresh and frozen–thawed TESE was used with or without motile sperm. Friedler *et al.* (1997) also found similar rates of fertilization and embryo implantation after ICSI with fresh or frozen–thawed testicular sperm in cases of non-obstructive azoospermia, but only used motile sperm.

Some case reports have been published of pregnancies following ICSI with frozen–thawed testicular motile sperm (Fisher *et al.*, 1996; Hovatta *et al.*, 1996; Podsiadly *et al.*, 1996; Khalifeh *et al.*, 1997), with fresh testicular motile sperm (Tournaye *et al.*, 1994; Devroey *et al.*, 1996) and with fresh testicular immotile sperm (Shulman *et al.*, 1999). Nagy *et al.* (1995) considered sperm motility to be the single most important factor associated with successful outcome of ICSI.

In 1998, the same authors performed a study designed to analyse the influence of motility on the results of 197 ICSI cycles. They reported that the normal fertilization rate was evidently lower (but acceptable) when non-motile testicular sperm was used in a subgroup of 14 patients. These reports did not describe any assessment of immotile sperm viability, so that the question arises as to whether such assessment was performed. If not, the lower rates achieved with immotile sperm may have been due to the use of at least some non-viable sperm. Our results of similar fertilization rates (with an admittedly small population size) contrast with those of Nagy *et al.* (1995), but the difference may be explained by our application of the fundamental criterion of vitality for immotile sperm selection.

The main limitation of this pilot study is the size of the study population with 61 patients (66 cycles). As they were divided into four groups, the statistical strength of the study is low.

To our knowledge, this is the first study to compare fertilization, pregnancy, implantation and take-home baby rates using fresh and frozen-thawed, motile and immotile sperm, where viability was determined mechanically. Immotility should not constitute a reason to reject morphologically normal sperm, especially in cases of minimal quantities where further biopsies may be counter-indicated, embarrass or inconvenience the patient, and consume health care resources.

This retrospective pilot study of 66 ICSI-TESE cycles showed no significant differences between rates of fertilization, implantation and normal pregnancy with frozen and fresh testicular sperm of normal morphology, whether motile or immotile.

Our results strongly suggest that viability of immotile spermatozoa can be assessed mechanically.

## References

- Barros A, Sousa M, Angelopoulos T and Tesarik J (1997) Efficient modification of intracytoplasmic sperm injection technique for cases with total lack of sperm movement. *Hum Reprod* 12,1227–1229.
- Casper RF, Meriano JS, Jarvi KA, Cowan L and Lucato ML (1996) The hypo-osmotic swelling test for selection of viable sperm for intracytoplasmic injection in men with complete asthenozoospermia. *Fertil Steril* 65,972–976.
- Devroey P, Nagy ZP, Tournaye H, Liu J, Silber S and Van Steirteghem A (1996) Outcome of intracytoplasmic sperm injection with testicular sperm in obstructive and non-obstructive azoospermia. *Hum Reprod* 11,1015–1018.
- Fisher R, Baukloh V, Naether O, Schulze W, Salzbrunn A and Benson DM (1996) Pregnancy after intracytoplasmic sperm injection of sperm extracted from frozen-thawed testicular biopsy. *Hum Reprod* 11,2197–2199.
- Friedler S, Raziel A and Soffer Y (1997) Intracytoplasmic injection of fresh and cryopreserved testicular sperm in patients with non-obstructive azoospermia: a comparative study. *Fertil Steril* 68,892–895.
- Hovatta O, Foudila T, Sieberg R, Johansson K, Smitten K and Reima I (1996) Pregnancy resulting from intracytoplasmic injection of sperm from a frozen-thawed testicular biopsy specimen. *Hum Reprod* 11,2472–2473.
- Khalifeh F, Sarraf M and Dabit S (1997) Full-term delivery following intracytoplasmic sperm injection with sperm extracted from frozen-thawed testicular tissue. *Hum Reprod* 12,87–88.
- Liu J, Tsai Y-L, Kartz E, Compton G, Garcia JE and Baramki TA (1997) High fertilization rate obtained after intracytoplasmic sperm injection with 100% nonmotile spermatozoa selected by using a simple modified hypo-osmotic swelling test. *Fertil Steril* 68,373–375.
- Nagy ZP, Liu J, Joris H, Verheyen G, Tournaye H, Camus M, Derde MC, Devroey P and Van Steirteghem AC (1995) The result of intracytoplasmic sperm injection is not related to any of the three basic sperm parameters. *Hum Reprod* 10,1123–1129.
- Nagy ZP, Joris H, Verheyen G, Tournaye H, Devroey P and Van Steirteghem AC (1998) Correlation between motility of testicular spermatozoa, testicular histology and the outcome of intracytoplasmic sperm injection. *Hum Reprod* 13,890–895.
- Palermo G, Joris H, Devroey P and Van Steirteghem AC (1992) Pregnancy after intracytoplasmic injection of a single spermatozoon into an oocyte. *Lancet* 304,17–18.
- Podsiadly BT, Woolcott RJ, Stanger JD and Stevenson K (1996) Pregnancy resulting from intracytoplasmic injection of cryopreserved sperm recovered from testicular biopsy. *Hum Reprod* 11,1306–1308.
- Schoysman R, Vanderzwalmen P, Nijs M, Segal-Bertin G and van de Casseye M (1993a) Successful fertilization by testicular sperm in an in vitro fertilization programme. *Hum Reprod* 8,1339–1340.
- Schoysman R, Vanderzwalmen P, Nijs M, Segal L, Segal-Bertin G, Geerts L, van Roosendaal E and Schoysman D (1993b) Pregnancy after fertilization with human testicular spermatozoa. *Lancet* 342,1237–1239.
- Shulman A, Feldman B, Madgar I, Levron J, Mashiach S and Dor J (1999) In vitro fertilization treatment severe male factor the fertilization potential of immotile spermatozoa obtained by testicular extraction. *Hum Reprod* 14,749–752.
- Tournaye H, Devroey P and Liu J (1994) Microsurgical epididymal sperm aspiration and intracytoplasmic sperm injection: a new effective approach to infertility as a result of congenital bilateral absence of the vas deferens. *Fertil Steril* 61,1045–1050.
- Tsai Y-L, Liu J, Garcia JE, Katz E, Compton G and Baramki TA (1997) Establishment of optimal hypo-osmotic swelling test by examining single spermatozoa from different hypo-osmotic solutions. *Hum Reprod* 12,11–113.
- World Health Organization (1992) *Laboratory Manual for the Examination of Human Semen and Sperm-Cervical Mucus Interaction*, 2nd edn. Cambridge University Press, New York.

Submitted on June 2, 2003; accepted on October 20, 2003